



**PATIENT**

Jim Dausen

**SPECIES**

Canine

**BREED**

Chihuahua

**SEX**

Male Neutered

**AGE**

8.5.16

**WEIGHT**

9.5lbs

**PRESENTING CLINICAL SIGNS**

History: Recheck echo. Grade 3/6 murmur stable from last year. Doing well.

-Current medications: Tussigon 5mg ¼-1/2 q6-12h.

-Sedation used: Not required to complete full diagnostic ultrasound.

-Pertinent previous ultrasound results (7/2021 MML): Mild MR, no LA or LVE, no TR.

-STAT: Declined.

-Imaging performed by: Stephanie Pearce RDCS, RVT.

**RADIOGRAPHIC FINDINGS \*NOTE: Images submitted for supplemental information only.**

Mild cardiomegaly. No obvious evidence of CHF.

**ECHOCARDIOGRAM FINDINGS**

2D, m-mode, color flow and doppler imaging is available. Diffuse thickening of mitral valve leaflets (anterior>posterior) with mild prolapse into the left atrial lumen. Moderate eccentric mitral regurgitation with moderate left atrial dilation. Normal MR velocity. Mild LV diameter with hyperdynamic myocardial function. The tricuspid valve appears subjectively normal, with no tricuspid regurgitation. Normal right atrial and ventricular diameter. The pulmonic and aortic valves are normal in morphology and mobility. Normal pulmonic and aortic outflow velocities. Mild to moderate aortic and no pulmonic insufficiency. No pericardial or pleural effusion noted. No cardiac tumors observed.

**CARDIAC CHART**

**INTERPRETED BY**

Maggie Machen Lamy,  
DVM, DACVIM  
(Cardiology)

**HOSPITAL NAME**

Northwind Animal  
Hospital

**REFERRING VET**

Dr. Cross

**INVOICE**

25066

**DATE**

6.29.22

| CANINE CARDIAC PARAMETERS  | MR VMAX (m/s) | TR VMAX (m/s) | LA/AO (Boon method) | LA/AO (Heart Base; Swe) | FS (%)                          | EF (%)                                   | EPSS (cm)                                |
|--|---------------|---------------|---------------------|-------------------------|---------------------------------|--|--|
| NORMAL PARAMETER   | 4.5-5.5       | <2.7          | 1.3                 | <1.6                    | 28-40                           | 40-100                                   | <0.6                                     |
| PATIENT  | 5.4           | NA            | NM                  | 1.8                     | 49                              | 82                                       | NM                                       |
| CANINE CARDIAC PARAMETERS  | HR (BPM)      | AV VMAX (m/s) | PV MAX (m/s)        | BODY WEIGHT (kg)        | LA 2D short axis Base view (cm) | LVIDd Avg; 2D and m-mode short axis (cm) | LVIDs Avg; 2D and m-mode short axis (cm) |
| NORMAL PARAMETER   | 50-100        | 0.7-1.7       | 0.7-1.6             | BELOW                   | BELOW                           | BELOW                                    | BELOW                                    |
| PATIENT  | 160           | 0.7           | 0.9                 | 4.3                     | 1.9                             | 2.7                                      | 1.4                                      |
| *Normal chamber parameters expressed as a mean value (SD)  |               |               |                     | 3                       | 1.27 (5.3)                      | 2.46 (2.46)                              | 1.36 (5.5)                               |
| BODY WEIGHT DEPENDENT PARAMETERS   |               |               |                     | 5                       | 1.40 (4.5)                      | 2.74 (5.2)                               | 1.60 (4.7)                               |
| *Note: All measurements based upon multi-modal images and methods. An average value is reported. |               |               |                     | 10                      | 1.50 (3.8)                      | 3.27 (3.5)                               | 2.06 (3.1)                               |
|  |               |               |                     | 15                      | 1.83 (2.0)                      | 3.71 (2.4)                               | 2.43 (2.1)                               |
|  |               |               |                     | 20                      | 2.02 (1.9)                      | 4.14 (2.2)                               | 2.80 (2.0)                               |
|  |               |               |                     | 25                      | 2.18 (2.4)                      | 4.48 (2.9)                               | 3.10 (2.5)                               |
|  |               |               |                     | 30                      | 2.33 (3.3)                      | 4.83 (3.9)                               | 3.39 (3.4)                               |
|  |               |               |                     | 35                      | 2.48 (4.3)                      | 5.17 (5.0)                               | 3.69 (4.5)                               |
|  |               |               |                     | 40                      | 2.62 (5.2)                      | 5.48 (6.1)                               | 3.96 (5.4)                               |
|  |               |               |                     | 50                      | 2.88 (7.1)                      | 6.07 (8.3)                               | 4.46 (7.4)                               |

Adapted from June Boon, Veterinary Echocardiography, 1998  
Rishniw M and Hollis NE, J Vet Intern Med 2000; 14:429-435  
Hansson et al, Vet Rad and Ultrasound 2002  
Bonagura et al. Echocardiography: principles of interpretation, Vet Clin North Am 15:1177, 1995

### INTERPRETATION OF THE FINDINGS & FURTHER RECOMMENDATIONS

Chronic degenerative valve disease persists with evidence of progression. Moderate mitral regurgitation has developed with increasing left heart dimensions. A significant aortic leak is noted, and a baseline blood pressure is recommended. No additional issues are identified.

Given these findings, Pimobendan is now indicated in this patient as below. Assessment of progression in the future will help predict long term outcome, however prognosis is guarded at this stage (B2).

Omega fatty acid supplementation and mild salt restriction may also be of some long-term benefit. Monitor for development of a progressive cough, labored breathing, exercise intolerance or collapse episodes.

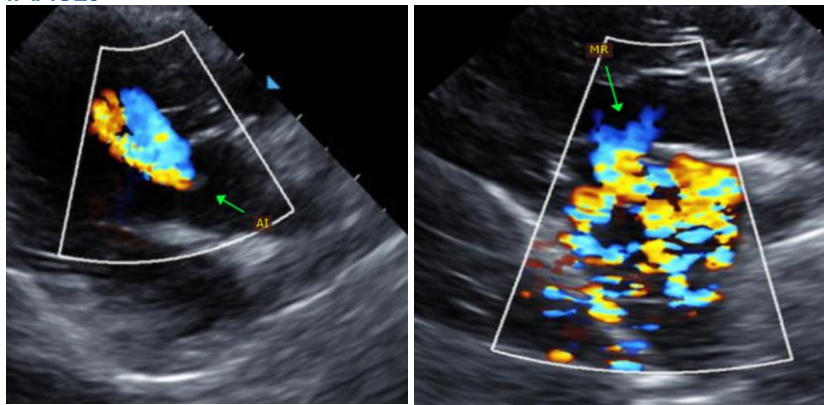
Once on the medication for 3-5 days, anesthetic risk is considered mildly elevated. Cardiac protective drug choices (opioid/benzodiazepine premedication, Propofol or alfaxalone induction, iso or sevo gas) are recommended. Monitor for arrhythmias, hypotension, and hypoxia both intra and post-operatively and intervene as necessary. Judicious IV fluid rates are recommended to avoid fluid overload. Avoid heart rate stimulating drugs such as atropine unless clinically indicated.

### PLAN

Baseline BP recommended. Institute heart muscle support Pimobendan 0.25-0.3mg/kg PO q12h.

Recommend monitor for progression with a recheck echocardiogram in 6 months, sooner if any development of clinical signs.

### IMAGES



**The information and recommendations provided are based on the images presented by the referring veterinarian. No evaluation can be communicated regarding pathology that was not visible in the image/video clips provided.**

Thank you for this referral. This report was generated using transcription software, and minor dictation errors may be present. If the clinical or image interpretation does not parallel your findings or if I can be of any further assistance, please contact me.

**Maggie Machen Lamy, DVM**  
**Diplomate of the American College of Veterinary Internal Medicine (Cardiology)**  
**info@sonopath.com**